



Summary Feedback

(Combined feedback broadcasted multiple time this week)

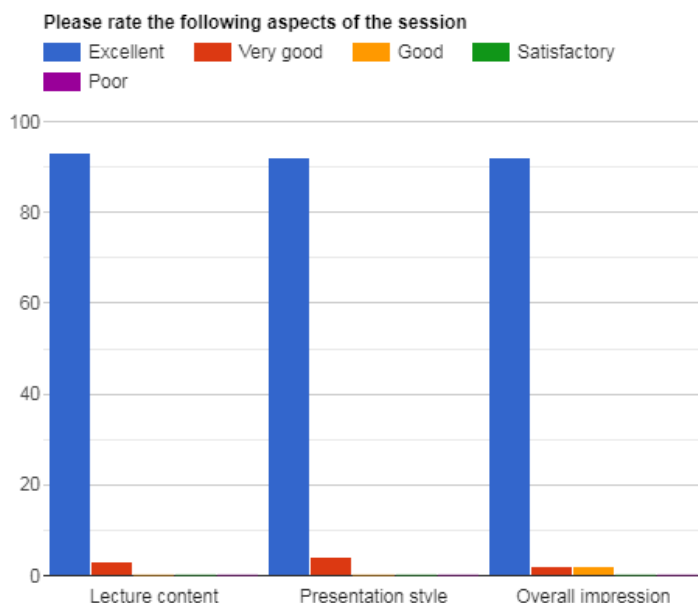
PRE-RECORDED: Basildon FRCR 2B 'A to Zee' Course 2020

Session 11/40

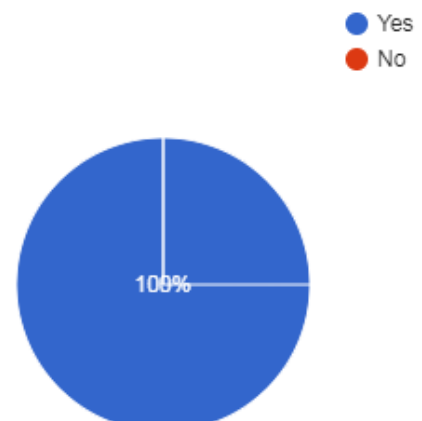
**GIT for FRCR Exam (Part - 1)
Plain Abdomen and Oesophagus
(13th & 14th July 2024)
Lecturer: Sami Khan**

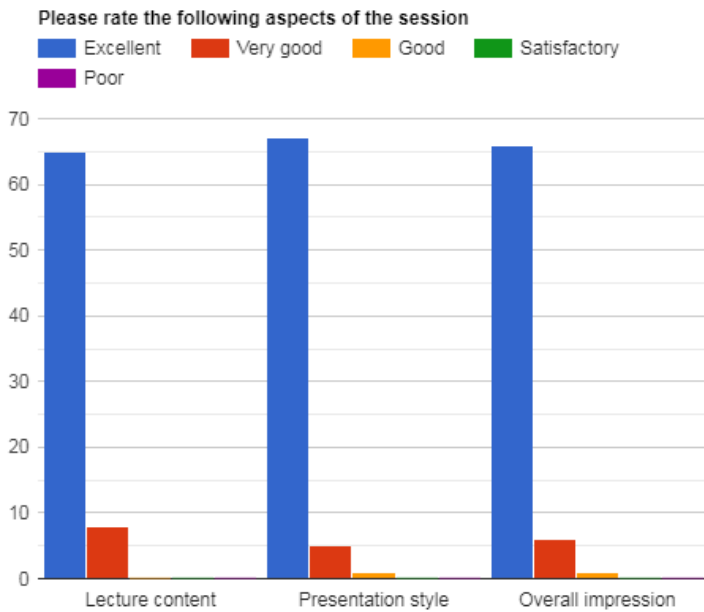
Summary Points:

- Total Attendees: 430 from 37 Countries (Algeria, Australia, Bahamas, Bangladesh, China, Dominica, Egypt, Ghana, Hong Kong, India, Indonesia, Iran, Iraq, Jordan, Kenya, Kuwait, Libya, Malaysia, Maldives, Myanmar, Nepal, Nigeria, Oman, Pakistan, Qatar, Saudi Arabia, Singapore, South Africa, Sri Lanka, Sudan, Swaziland, Türkiye, UAE, UK, Yemen, Zambia, Zimbabwe).
- Total duration: 2 hours & 45 minutes (each session broadcasted thrice during the week)
- Total feedback received from 180 participants, from three different broadcasts

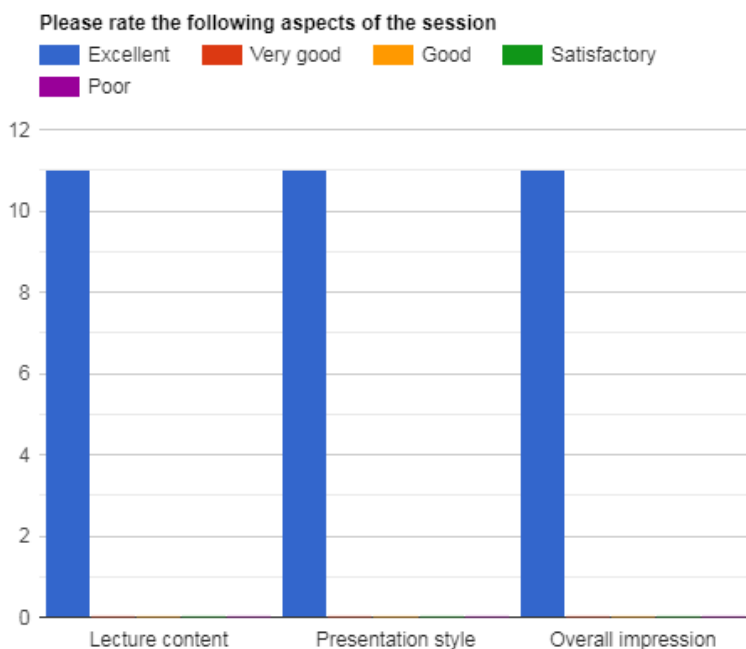
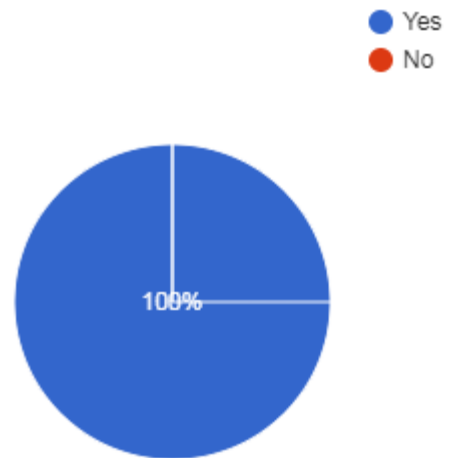


Did you find it useful
96 responses

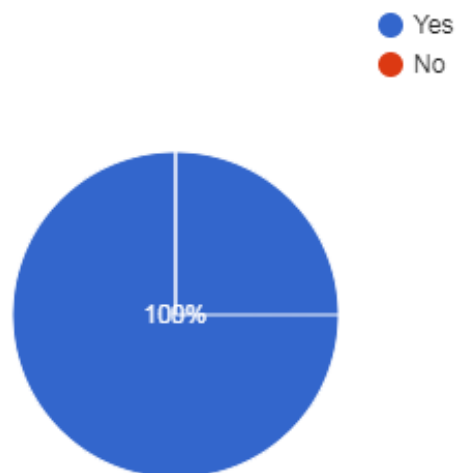




Did you find it useful
73 responses



Did you find it useful
11 responses



Testimonials

- Excellent! I am blessed to be part of Dr Khan's teaching. Thank you sir for your invaluable efforts to teach us and make us a good radiologist (India).
- Always waiting for more. Your lectures sir makes me alert & concentration along its whole length. Thank you so much sir. I'm very sad that I missed the first 9 lectures of this course (Egypt).
- Excellent choice of cases with the best explanation by a great teacher, Dr Khan! (Pakistan).
- The cases and concepts of pathology explanations were excellent. The imaging came out better this session. I could see more plain film pathology. Going through the reasons for contrast and where certain ones were contraindicated was very useful (UK).
- I got sound knowledge of different abdominal X-ray films interpretation. Very good explanation of each case (Pakistan).

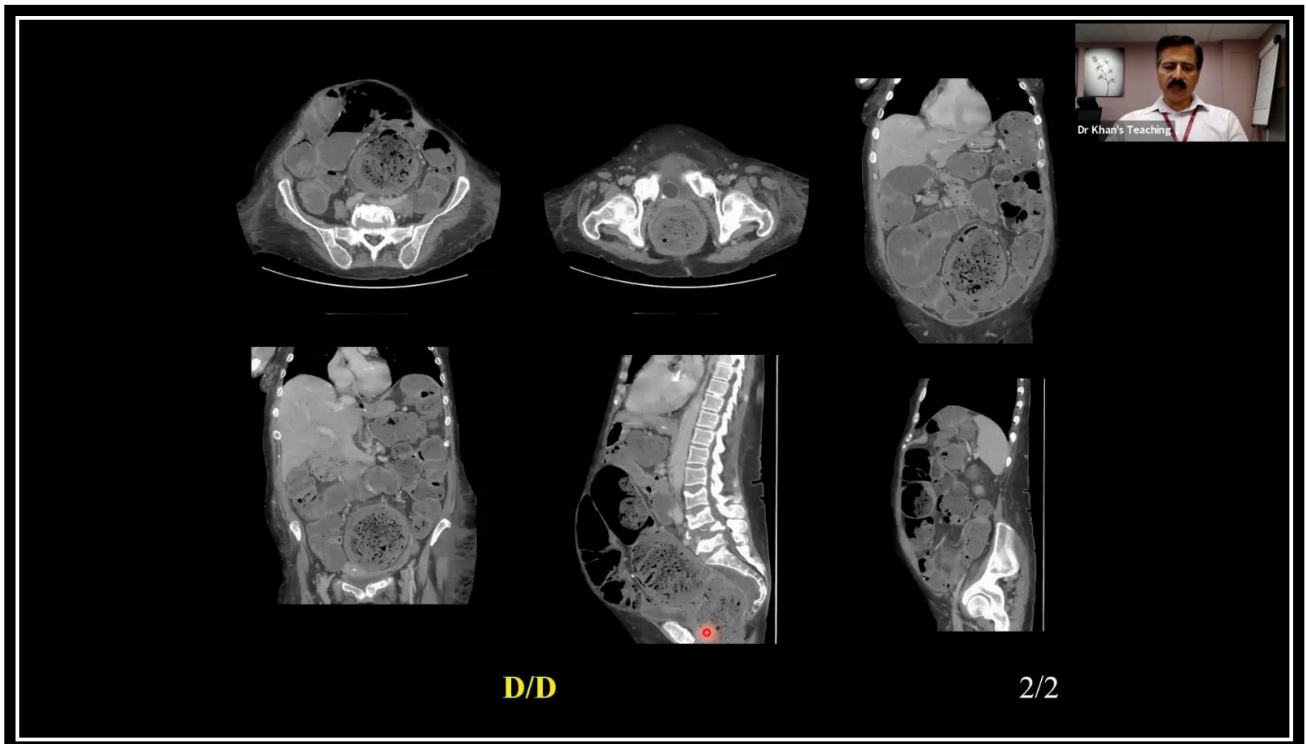
GIT for FRCR Exam (Part - 1) Plain Abdomen and Oesophagus

- Really good to have AXR and contrast study teaching as these subjects are often neglected. Great clarification of whether oesophageal ca is operable or non-operable. Explains principles underlying imaging findings was useful (UK).
- The gentle but impactful teaching style (Nigeria).
- I liked the teaching modes and a lot of question, matching large numbers of candidates. This allows audience to digest as well before final answers are given (South Africa).
- Excellent Dr Sami, doing a fantastic job (India).
- Excellent teaching from Dr Khan as always (Saudi Arabia).
- Good mix of cases and explanations. Also useful to learn from candidates' mistakes (UK).
- The post-surgical contrast studies, acute abdomen plain films and the appearance of diverticula in the pharynx and oesophagus were the most helpful (UK).
- This is all good lecture, recorded versions are desirable (Australia).
- The importance of differentiation of small bowel valvulae from large bowel was useful (Sudan).
- Massive academic information (Pakistan).
- I liked the way of executing the lecture and the type of teaching (Pakistan).
- Dr Khan's sessions are perfection (Pakistan).
- Well explained. Just love the way you teach sir. You are inspiration sir (Nepal).
- Excellent lecture with good exam oriented topics (India).
- Great teaching (Pakistan).
- X-ray images are very good (India).
- Excellent teaching (Sri Lanka).
- All aspects are valuable and useful (India).
- Drug mules: I see in first time in X-ray abdomen (Sri Lanka).
- Amazing collection of cases (India).
- Content and delivery was useful (UK).
- Interpretation of abdominal X-ray was most useful (UK).
- Content and explanation was useful (UK.)
- The cases and discussion was useful (Egypt).
- Thank you very much for covering from basics (UK).
- Dr. Khan's to the point explanations of high yield points were the most useful (Pakistan).
- A lot of conventional X-ray films was useful (Qatar).
- Dr Khan was very humble and moral boosting (Saudi Arabia).
- Life's aspects was useful (India).
- Abdominal X-ray which is usually everyone's weak point was most useful (UK).
- I liked the emergency in GIT (India).
- Mind storming excellent cases (Pakistan).
- The variety of cases is so important and very useful (Iraq).
- The cases reviewed was most useful (Nigeria).
- All the content was useful (Sri Lanka).
- Good case collection (Maldives).
- It was perfect (UAE).
- All cases and discussion was useful (UAE).
- Nice explanation and cases (Iraq).
- Using EUS for T-staging of esophageal ca, idiopathic Pneumatosis intestinalis, various abdominal calcifications and uses of contrast were useful (Zimbabwe).
- Type of contrast, aunt Minnie cases and staging of oesophageal cancer was useful (UK).
- Way of discussion was useful (Iraq).

GIT for FRCR Exam (Part - 1) Plain Abdomen and Oesophagus



- Good explanation and idea of thinking were most useful valuable for me (Myanmar).
- As usual all of it was very useful & added new information (from just AXR lots of information could be extracted) (Egypt).
- Excellent teaching! (UK).
- It's perfect sir really (Egypt).
- Excellent lecture (India).
- Very nice explanations (India).
- Excellent teaching always (UK).
- Very illuminating (Nigeria).
- Excellent informative session thanks (Yemen).
- Great one, thank you (Iraq).
- Impressive (Iraq).
- Excellent delivery of the lecture (Nigeria).
- Awesome session (India).
- Well presented (Nigeria).
- Brilliant session (South Africa).
- Super Excellent (Nigeria).
- Great learning (Pakistan).
- Very informative (Saudi Arabia).
- Brilliant session (Pakistan).
- Starting from very basics plus showing some classical cases and new advancements was most useful (Pakistan).
- I liked the detailed review of esophageal pathologies on fluoroscopy (Pakistan).
- Academic and exam tips were the most helpful (Pakistan).
- Nice mix of cases and the use of contrast (UK).
- Love from India (India).
- Basics, tips for exam and case based learning were the most useful (South Africa).
- Excellent cases and discussion (India).
- Excellent teaching (Malaysia).
- All the acute cases were helpful (Egypt).
- Excellent teaching (Malaysia).
- The introduction given was the most useful (Australia).
- Good AXR cases (UK).
- Pattern recognition was helpful (India).
- Very well presented and good teaching point (South Africa).
- Cases, dissection and the teaching points were the most useful (Sudan).
- Interesting cases and valuable information (Algeria).
- Everything was helpful, especially the radiograph spotters (Malaysia).
- Good approach and exam tips were the most useful (Zimbabwe).
- Great variety of x-rays and pathologies (UK).
- Great teaching, great cases (Libya).
- Wonderful teaching (UK).
- Excellent exam oriented teaching and discussion (Sri Lanka).
- The UK system based knowledge was amazing (Pakistan).
- I liked the cases from barium studies and the exam tips (Sri Lanka).
- The fluoroscopy cases were the most useful (UK).
- Barium and acute abdomen cases were the most useful (India).

- 'CT and EUS staging if esophageal CA clarified' was the most helpful aspect (Zimbabwe).
- Lots of new concepts was useful (Pakistan).
- Dr Khan's explanations and teaching was useful (Pakistan).
- Training your eyes and imagination was very useful (Australia).
- Wonderful teaching on CA esophagus and abdominal X-Ray approach (UAE).
- I liked the emphasis on approach to exam film and discussion on differentials (Pakistan).
- Most useful for daily practice and exam (Myanmar).



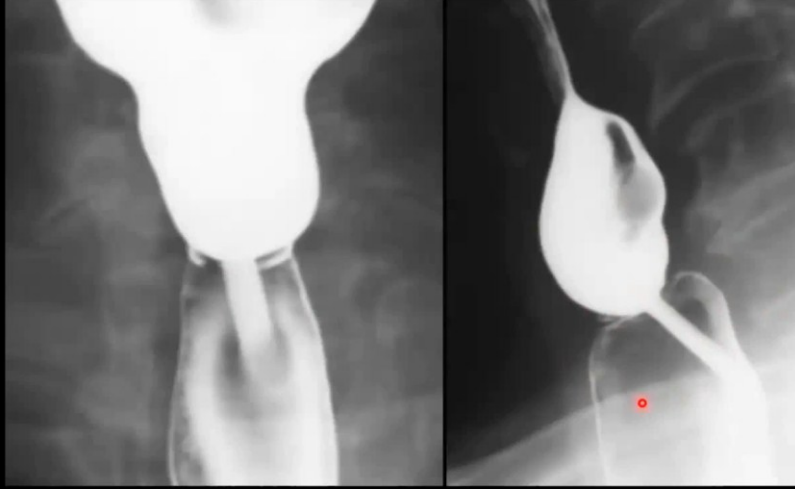
What is the role of Decubitus view?

- Suspected pneumoperitoneum, if the patient cannot stand



Bontrager : Textbook of Radiographic Positioning

73 male-discomfort while eating



ACR

1/2

Dr Khan's Teaching

=====XX=====XX=====